



Three-dimensional NLS-graphy of joints in diagnostics of early rheumatoid arthritis

has increased greatly in the last decade because of development and introduction into clinical prac-

-

-

-

-

-

-

-

-

-

-

-

-

-

-

-

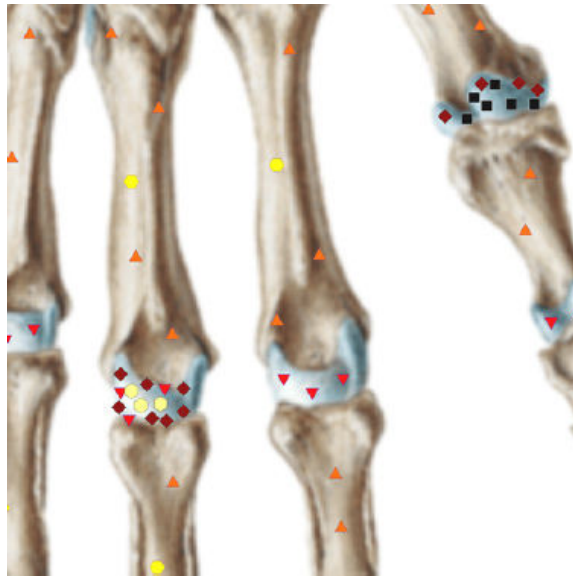
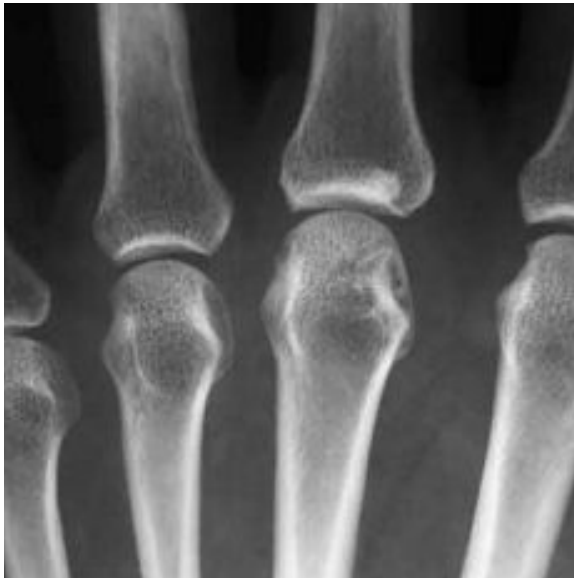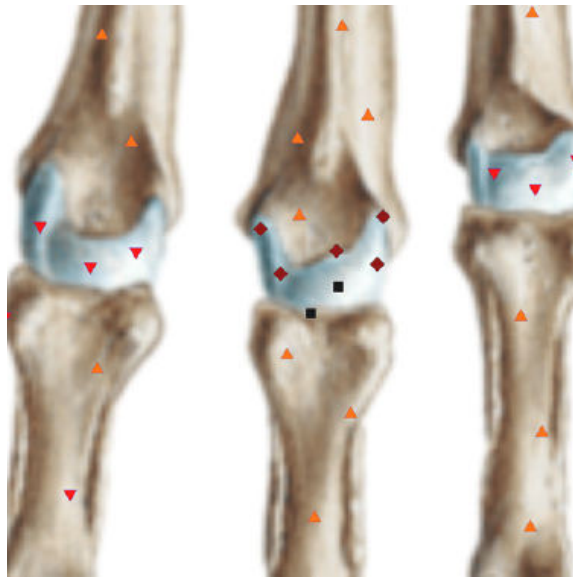
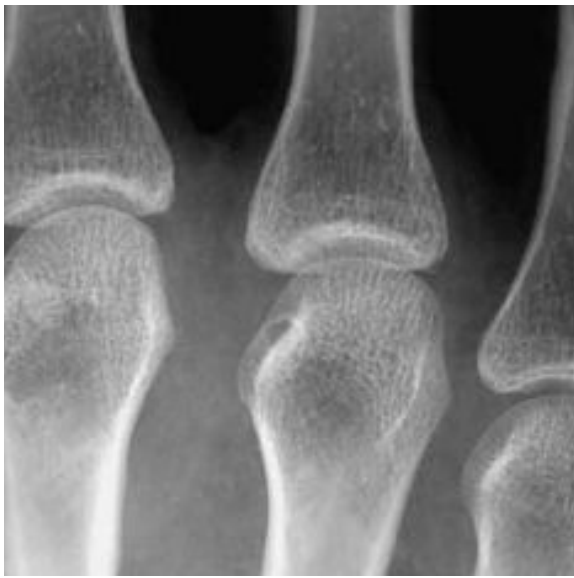-

-

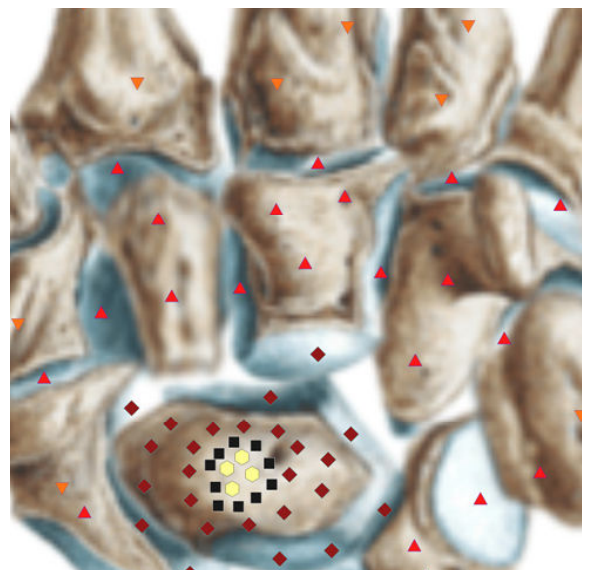
-

-

-



SYNOVITIS



OSTITIS

-
-
-
-

-
-
-

-

-

-

-

-

-

-

-

