



# Combined NLS-diagnostics of orbital cellulitis

-

-

-

-

-

-

-

-

-

-

-

-

-

-

-

-

-

-

-

-

-

-

-

-

-

-

-

-

-

-

-

-

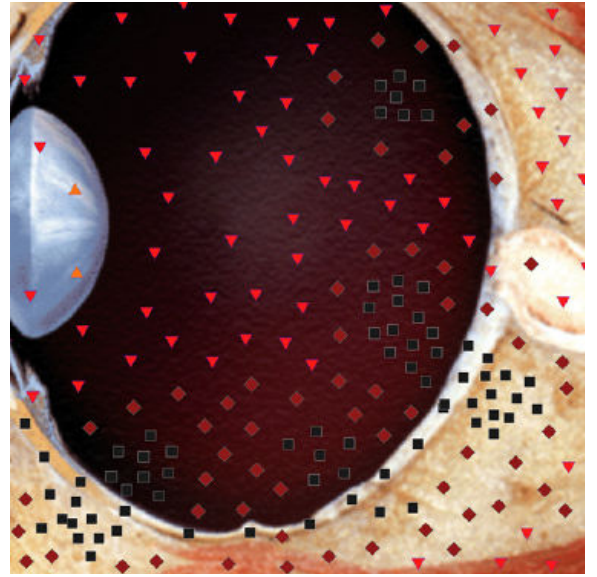
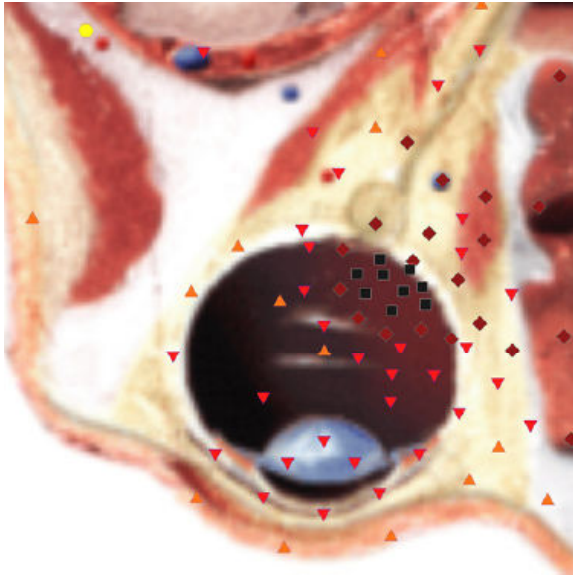
-

-

-

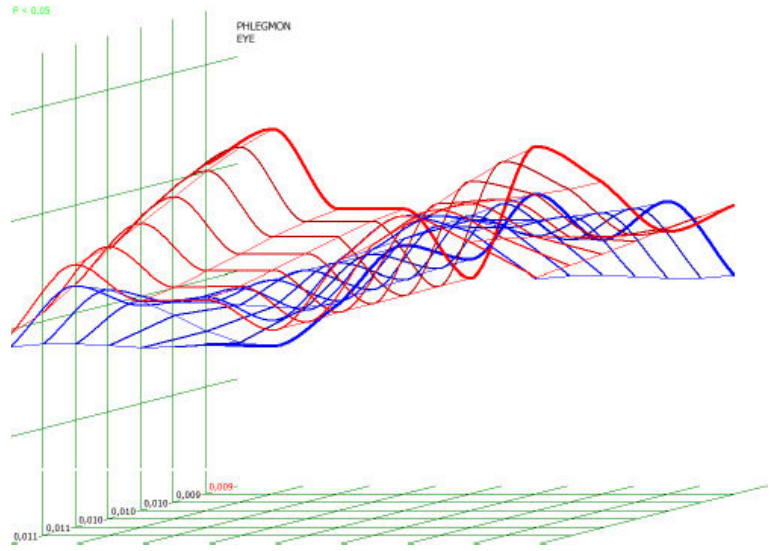
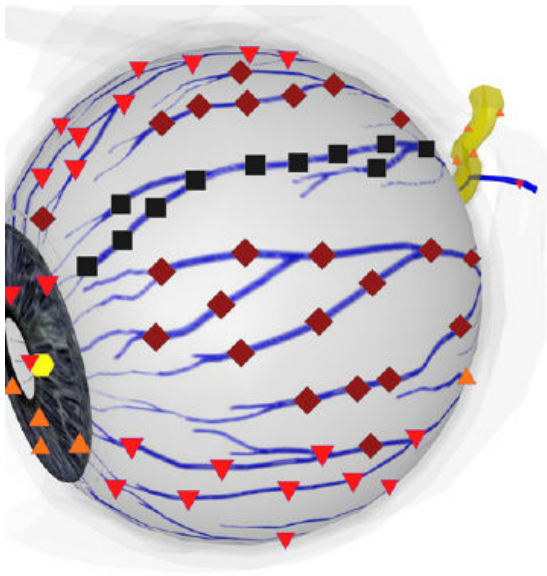
-

-



neity of retrobulbar tissue and affection of

- Increased chromogeneity of retrobulbar



-  
-